

Motor Nerve to the Vastus Lateralis

Peter C. Revenaugh, MD; P. Daniel Knott, MD; Jennifer M. McBride, PhD; Michael A. Fritz, MD

Objective: To further delineate the anatomy of the motor nerve to the vastus lateralis (MNVL) in the context of its use as a possible interpositional nerve graft in facial nerve rehabilitation.

Methods: Twelve fresh human cadaveric thighs were dissected to investigate the anatomic location and branching pattern of the MNVL muscle.

Results: There were 3 to 6 primary nerve branches (mean, 4.4) supplying the vastus lateralis. The mean primary branch length was 93.8 mm (range, 51-196 mm), and each primary branch had a mean of 2.3 subsequent branches.

There were 2 larger caliber branches (>2 mm in diameter) supplying the proximal and distal muscle. The nerve branches are variable in their relation to the vascular pedicle and perforating vessels of the descending branch of the lateral circumflex femoral artery.

Conclusion: The nerve to the vastus lateralis is a readily available, redundant motor nerve suitable for facial nerve cable grafting.

Arch Facial Plast Surg. 2012;14(5):365-368.

Published online April 16, 2012.

doi:10.1001/archfacial.2012.195

FACIAL NERVE PARALYSIS IS A potentially devastating cranial nerve injury with both functional and psychological impact. Neural compromise following tumor resection or in cases of traumatic and iatrogenic injury can be treated in several ways. Direct anastomosis is the preferred treatment in cases of neurotmesis if there is sufficient length to provide a tension-free coaptation. If direct anastomosis is not possible, a cable graft spanning the interrupted segment is accomplished with an autologous nerve. Resection of malignant tumors affecting the facial nerve commonly results in large segments of neural discontinuity that may involve several branches of the facial nerve.

Reconstruction of complicated craniofacial defects often necessitates free tissue transfer. The anterolateral thigh (ALT) free flap is a versatile and reliable soft-tissue microvascular flap. During harvest of the ALT flap, the motor nerve to the vastus lateralis muscle (MNVL) is commonly encountered in close proximity to the vascular pedicle.¹ The nerve has been noted to be redundant in its course, and its multiple-branching pattern is ideal for reconstitution of multiple facial nerve branches. However, controversy exists regarding the sequelae of nerve resection during flap harvest.^{2,3} There is a paucity of literature describing the typical course of the MNVL. Furthermore, there is little discussion regarding potential use of the MNVL as a cable nerve graft. Herein, we

describe the anatomic distribution of the MNVL in cadaveric dissections and discuss the novel use of the nerve as a cable graft in facial nerve grafting.

METHODS

The study involves both anatomic dissection and description of clinical cases. First, an anatomic cadaveric study was performed using fresh cadavers bequeathed to the Cleveland Clinic Body Donation Program (Cleveland, Ohio). Dissections were performed under the supervision and guidance of anatomy faculty in the Cleveland Clinic Lerner College of Medicine who oversee this program. The institutional review board of the Cleveland Clinic approved this study.

Twelve fresh human cadaveric thighs from 6 cadavers were dissected to describe the course of the MNVL. Incisions were made in the skin from the anterior superior iliac crest to the lateral patella, and the tensor fascia lata muscle was incised along this length for optimal exposure. Under loupe magnification, the nerve was located proximally at the inguinal ligament and dissected distally, coursing between the rectus femoris muscle and the vastus lateralis muscle. The main trunk and its subsequent divisions were traced distally. Primary nerve branches were defined as those arising from the bulk of the descending nerve. Any further arborization beyond the primary branches was considered a secondary branch. Each branch (primary or secondary or both) was measured using a standard surgical ruler. When necessary, the vascular pedicle was divided to follow the course of the nerve and obtain accurate measurements. The relation of the nerve to the vascular pedicle was also recorded.

Author Affiliations:
Department of Otolaryngology–Head and Neck Surgery, Head and Neck Institute (Drs Revenaugh and Fritz), and Lerner College of Medicine, Case Western Reserve University (Dr McBride), Cleveland Clinic, Cleveland, Ohio; and Department of Otolaryngology–Head and Neck Surgery, University of California San Francisco, San Francisco (Dr Knott).

RESULTS

The nerve to the vastus lateralis was found to branch extensively as it coursed distally through the thigh. There were 3 to 6 primary nerve branches (mean, 4.4) supplying the vastus lateralis in each thigh (**Figure 1**). The mean branch length was 93.8 mm (range, 51-196), and each primary branch had an average of 2.3 secondary branches (**Table**).

In each specimen there were at least 2 larger branches (>2 mm in diameter) supplying the proximal and distal muscle. The nerve branches are variable in their relation to the vascular pedicle and perforating vessels of the descending branch of the lateral circumflex femoral artery (DLCFA).

COMMENT

The vastus lateralis is the largest of the quadriceps muscles. It receives motor innervation through a branch of the femoral nerve, namely the MNVL. Although the vascular supply and sensory innervation of the lateral thigh have been well described, there are few studies addressing the mo-

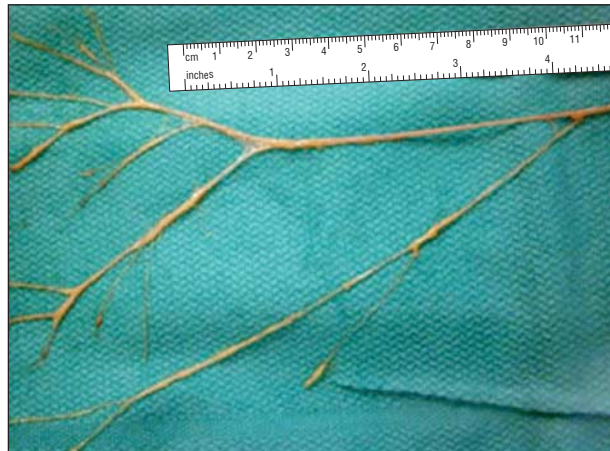

Figure 1. Anatomic specimen of the nerve to the vastus lateralis with extensive arborization.

tor neural supply.⁴ Patil et al⁵ described 2 to 3 main divisions of the nerve in 10 limbs and what appeared to be a proximal and distal division of the nerve. Our investigation yielded similar findings, with proximal nerve branching occurring high in the thigh. The distal division corresponds to the portion of the nerve often encountered in ALT dissection, and the distal nerve was observed to branch more robustly than the proximal nerve in our dissections (Figure 1).

The MNVL is variably related to the DLCFA, the nutrient vessel most commonly associated with the ALT flap (**Figure 2** and **Figure 3**). Casey et al¹ retrospectively reported that 7% of ALT flap harvests had a relationship of the nerve and vascular pedicle that was unfavorable for uncomplicated flap harvest. Rozen et al² defined 3 potentially deleterious variations of the nerve-pedicle relationship. In their study, 28% of 36 thighs had 1 of the described variations. Type 1 is defined as a motor nerve passing through the vascular pedicle. Type 1 variations are further subdivided into type 1a, in which a motor nerve passes through a perforator from the DLCFA, and type 1b, in which a motor nerve passes through the main vascular pedicle. In a type 2 variation, the nerve passes between 2 adjacent perforators of the flap.² We observed a type 1a variation in 3 specimens and a type 2 variation in 2 specimens (Table). This accounted for 42% of specimens with 1 of these anatomic variations, a rate slightly higher than previously reported. We would expect that with a greater number of dissections, this number would reduce.

Because the nerve can be intimately associated with the pedicle, there are occasions when sacrifice of a branch or branches of the nerve is necessary for safe flap harvest. Kuo et al⁶ suggest that there may be weakness of the quadriceps femoris when there is harvest of a portion of the vastus lateralis muscle. However, they did not specifically study the effects of nerve sacrifice. In a series of 220 ALT harvests, the nerve had to be transected 22% of the time, and postoperative lower extremity weakness was not found to be related to nerve sacrifice.³ Furthermore, all patients with complaint of weakness postoperatively had resolution of their subjective weakness

Table. Anatomic Details of the Motor Nerve to the Vastus Lateralis From 12 Cadaver Lower Limbs

Specimen No.	Primary Branches, No.	Primary Branch Length, Mean, mm	Maximum Primary Branch Length, mm	Secondary Branches per Primary Branch, Mean, No.	Type of Relationship to Vascular Pedicle ^a
1	4	147.3	195	4.3	1a
2	4	118.3	196	2.5	0
3	4	86.8	106	2.5	2
4	4	143.3	244	4.5	0
5	6	95.3	127	1.8	1a
6	5	73.6	98	1.8	0
7	3	108.7	129	2.6	2
8	5	103.4	153	2.6	0
9	6	138.3	250	3.0	1a
10	3	97.3	126	3.0	0
11	6	144.8	171	2.0	0
12	5	77.6	127	2.0	0

^aThe numbers indicate the following: 0, the nerve is not involved with pedicle; 1a, the motor nerve passes through a perforator from the descending branch of the lateral circumflex femoral artery (DLCFA); 1b, the motor nerve passes through the main vascular pedicle of the DLCFA; 2, the motor nerve passes between 2 adjacent perforators.

by 6 months. These data suggest that harvest of a portion of the MNVL does not impair overall lower extremity function. This may be related to the redundancy of the nerve supply to the muscle or to the possibility of reinnervation.

The apparent redundancy and lack of consequences with nerve sacrifice make the MNVL an enticing option

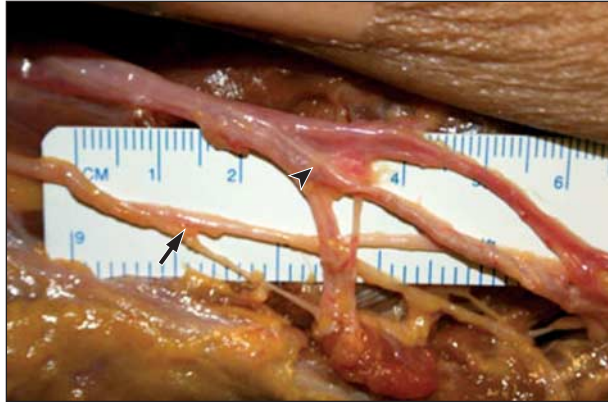

Figure 2. Relation of the nerve to the vastus lateralis (arrow) to the descending branch of the lateral femoral circumflex artery (arrowhead).

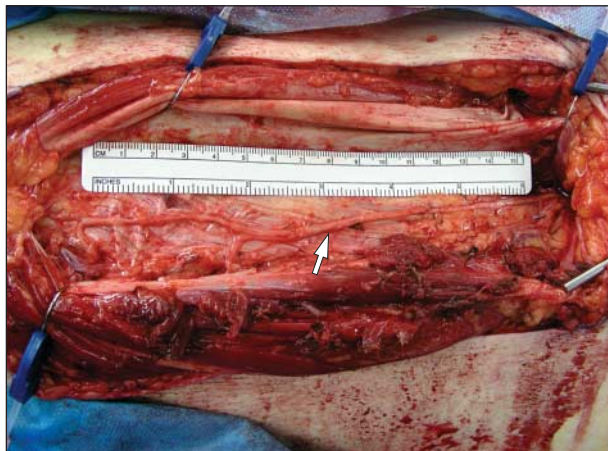

Figure 3. The large-caliber, redundant motor nerve to the vastus lateralis (arrow) courses along the ALT resection bed in a flap harvest.

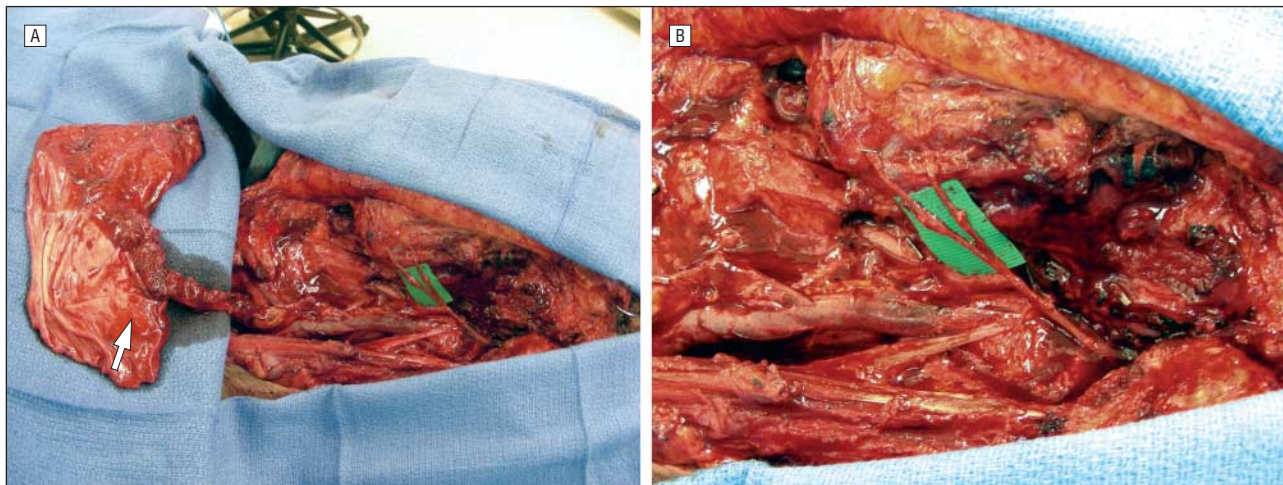


Figure 4. Example of use of nerve to vastus lateralis in facial nerve reconstruction. A, Nerve graft in place with revascularized anterolateral thigh fat/fascia flap for reconstruction (arrow). B, Close-up of nerve graft to 2 facial nerve branches.

for cable grafting. Traditionally, cable grafting for facial nerve repair has been accomplished with sensory nerves, including the great auricular, sural, or medial and lateral antebrachial cutaneous nerves.⁷ Although it is clear that nerve regeneration can be accomplished regardless of donor nerve modality, there is evidence that matching modality of donor and recipient nerve for grafting may provide optimal results. In rat femoral and tibial nerve repair models, motor and mixed motor-sensory donor nerves provided enhanced motor nerve regeneration over purely sensory donor nerves, termed “preferential reinnervation.”^{8,9}

Aside from the advantages as a motor nerve, the MNVL provides several other advantages over the most commonly used sensory nerve interpositional grafts. When including 1 or more branches, the MNVL can provide grafts more than 30 cm in length, rivaling the length of sural nerve grafts without the need for leg incisions.⁷ In addition, using the MNVL obviates sensory deficits associated with sural and medial antebrachial cutaneous nerve harvest. The multiple-branching pattern of the MNVL is optimal for facial nerve grafting in cases in which several branches may need to be grafted. Ideally, with resection of the facial nerve, frontal, orbital, and marginal mandibular branches important for eye closure and oral competence should be preferentially reanimated. To graft multiple branches, sural, great auricular, and antebrachial cutaneous nerves may require splitting that could reduce the number of available axons for regeneration and may damage the nerve substance.¹⁰ In addition, when compared with sural nerve grafts, the nerve caliber of MNVL provides a more optimal match with facial nerve branches, potentially offering more reliable outcomes.

The MNVL is well suited for both interpositional and potentially for cross-facial grafts. In settings in which more complicated reconstruction is required, such as in radical parotidectomy defects, the nerve can be harvested at the same time as ALT soft-tissue flaps and/or fascia lata for suspension or an adjunct to temporalis tendon transfer. In our early experience we harvested the nerve with either an ALT flap or tensor fascia lata or as a stand-alone graft (**Figure 4**). We have not observed any do-

nor site complications. All patients returned to their preoperative ambulatory level of function.

Harvest of the MNVL requires nominal increase in operative time, especially when harvested in conjunction with ALT flaps or tensor fascia lata. In the setting of radical parotidectomy reconstruction, in which other soft-tissue techniques are to be used and local nerve sources (eg, great auricular) are not adequate, we advocate cable grafting with a branch of MNVL because it does not seem to provide additional morbidity and has favorable length, caliber, and branching patterns in comparison with other distant harvest sites, such as the sural or medial antebrachial cutaneous nerve.

Potential disadvantages of MNVL harvest would include an incision along the lateral thigh. However, an incision along the thigh may be preferred over a calf incision and lateral foot anesthesia (sural nerve harvest) or medial arm incision and medial forearm anesthesia (medial antebrachial cutaneous nerve harvest) in some patients. Although no apparent long-term motor dysfunction is anticipated as a result of MNVL harvest, prospective studies with preoperative and postoperative strength testing should be accomplished to confirm this observation.

In conclusion, the MNVL is a multiple-branching motor nerve commonly associated with the descending branch of the lateral femoral cutaneous artery. It is observed during ALT flap dissection and can be harvested without additional morbidity to the patient, providing favorable graft length, caliber, and branching pattern. Interpositional grafting of facial nerve discontinuity using a portion of the motor nerve to vastus lateralis provides the potential for facial tone reconstitution and mimetic functional recovery.

Accepted for Publication: February 13, 2012.

Published Online: April 16, 2012. doi:10.1001/archfacial.2012.195

Correspondence: Michael A. Fritz, MD, Department of Otolaryngology–Head and Neck Surgery, Head and Neck Institute, Cleveland Clinic, 9500 Euclid Ave, Desk A71, Cleveland, OH 44195 (fritzml@ccf.org).

Author Contributions: *Study concept and design:* Revenaugh, Knott, and Fritz. *Acquisition of data:* Revenaugh and McBride. *Analysis and interpretation of data:* Revenaugh and Fritz. *Drafting of the manuscript:* Revenaugh. *Critical revision of the manuscript for important intellectual content:* Revenaugh, Knott, McBride, and Fritz. *Statistical analysis:* Revenaugh. *Obtained funding:* Revenaugh. *Administrative, technical, and material support:* Revenaugh, McBride, and Fritz. *Study supervision:* Knott and Fritz.

Financial Disclosure: None reported.

Previous Presentation: This study was presented at the Annual Meeting of the American Academy of Facial Plastic and Reconstructive Surgery; September 10, 2011; San Francisco, California.

REFERENCES

1. Casey WJ III, Rebecca AM, Smith AA, Craft RO, Hayden RE, Buchel EW. Vastus lateralis motor nerve can adversely affect anterolateral thigh flap harvest. *Plast Reconstr Surg.* 2007;120(1):196-201.
2. Rozen WM, le Roux CM, Ashton MW, Grinsell D. The unfavorable anatomy of vastus lateralis motor nerves: a cause of donor-site morbidity after anterolateral thigh flap harvest. *Plast Reconstr Surg.* 2009;123(5):1505-1509.
3. Hanasono MM, Skoracki RJ, Yu P. A prospective study of donor-site morbidity after anterolateral thigh fasciocutaneous and myocutaneous free flap harvest in 220 patients. *Plast Reconstr Surg.* 2010;125(1):209-214.
4. Zhang Q, Qiao Q, Gould LJ, Myers WT, Phillips LG. Study of the neural and vascular anatomy of the anterolateral thigh flap. *J Plast Reconstr Aesthet Surg.* 2010;63(2):365-371.
5. Patil S, Grigoris P, Shaw-Dunn J, Reece AT. Innervation of vastus lateralis muscle. *Clin Anat.* 2007;20(5):556-559.
6. Kuo YR, Jeng SF, Kuo MH, et al. Free anterolateral thigh flap for extremity reconstruction: clinical experience and functional assessment of donor site. *Plast Reconstr Surg.* 2001;107(7):1766-1771.
7. Humphrey CD, Kriet JD. Nerve repair and cable grafting for facial paralysis. *Facial Plast Surg.* 2008;24(2):170-176.
8. Kawamura DH, Johnson PJ, Moore AM, et al. Matching of motor-sensory modality in the rodent femoral nerve model shows no enhanced effect on peripheral nerve regeneration. *Exp Neural.* 2010;223(2):496-504.
9. Brenner MJ, Hess JR, Myckatyn TM, Hayashi A, Hunter DA, Mackinnon SE. Repair of motor nerve gaps with sensory nerve inhibits regeneration in rats. *Laryngoscope.* 2006;116(9):1685-1692.
10. Yarbrough WG, Brownlee RE, Pillsbury HC. Primary anastomosis of extensive facial nerve defects: an anatomic study. *Am J Otol.* 1993;14(3):238-246.